

muscle edge, with the region of interest containing the pectoral muscle. Wavelet filters used to detect pectoral muscle are chosen by knowing the approximate angle of the muscle. Finally, a post-processing stage is used to find the true pectoral muscle edge by selecting only valid lines that are pectoral muscle boundary. In order to segment the pectoral muscle region Aylward et al. [16] used gradient magnitude ridge traversal algorithm at a small scale and at multiple initial points. They resolved the resulting multiple edge definitions via a voting scheme. Raba et al. [8] presented an automated technique for segmenting a digital mammogram into breast region and background with pectoral muscle suppression. They used region growing intensity threshold estimation to locate the pectoral muscle. Mirzaalian et al. [17] presented an approach for pectoral muscle segmentation based on nonlinear diffusion algorithm. Kwok et al. [18] proposed adaptive algorithm that uses knowledge about the position and shape of the pectoral muscle on mediolateral oblique views. The pectoral edge is first estimated by a straight line which is validated for correctness of location and orientation. This estimate is then refined using iterative "cliff detection" to delineate the pectoral margin more accurately. Finally, an enclosed region that represents the pectoral muscle is generated as a segmentation mask.

This paper presents a method for breast skin-air boundary and pectoral muscle detection on digital mammography images. Breast skin-air interface is determined by finding the breast border contour. The border contour is found by a simplified region growing algorithm which can be used because of very good quality images. For pectoral muscle detection a hybrid method is proposed. This method uses reduction in image bit depth to obtain more contrast in the image for easier edge detection. For the process of edge detection, approximation images of the fourth level dyadic wavelet decomposition are being used. After edge detection that uses the Sobel filter a smoothened curve is drawn to segment the pectoral muscle area. In this way, segmented pectoral muscle can easily be removed or its coordinates can be used for image registration process. Test set of images is obtained from digital mammography device. The images are stored in compliance with the Dicom standard in TIFF image format.

The rest of the paper is organized as follows: in Section II breast segmentation technique is described. In Section III algorithm for pectoral muscle detection is explained. In Section IV experimental results are presented. Section V draws the conclusion.

II. BREAST SEGMENTATION

Process of breast segmentation is the first step in mammography image analysis. It is important to find the skin-air interface, or the breast contour, and define the region of interest (ROI) for further analysis. Breast contour extraction is somewhat easier on higher

quality digital mammography images than on digitized screen film mammography images. The reason for that is the absence of objects outside of the breast border and preprocessing that has been done by the mammography device. Digital mammography images are mostly stored in compliance with the Dicom standard. That means that each image contains a header with information about patient, procedure and many technical details concerning imaging device and operating conditions. In Dicom header it is possible to find the information such as view position of the breast and laterality to determine whether the image of the left or the right breast is viewed. That helps in finding proper coordinates of the starting point for finding breast border. Our algorithm for finding breast border contour proposed in this paper is described by the flowchart shown in Fig. 1.

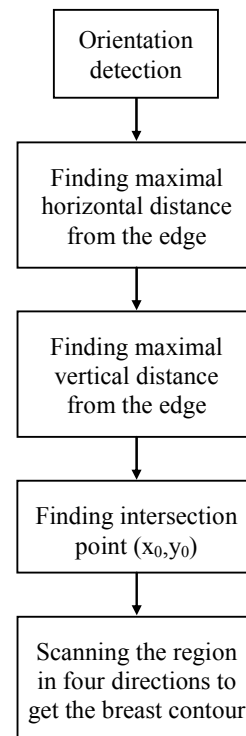


Fig. 1 – Breast border contour algorithm flowchart

In the first step it is important to determine intensity value of the background to be able to find pixels that create the border line. The first objective in segmentation process is to determine the breast orientation, if that information is not possible to obtain from header of the image. Orientation is found by scanning the centre horizontal line of the image from the left and right side until pixel values are higher than the background and determining which of these two distances is shorter. After the orientation is known, the centre of the breast must be found. Centre of the breast is determined by the point of intersection of two perpendicular straight lines, one horizontal and one vertical. These lines are determined in a way that each line is positioned at the coordinate where

maximal distance of breast tissue from the image edge is found, as shown in Fig. 2. The found coordinate is named (x_0, y_0) .

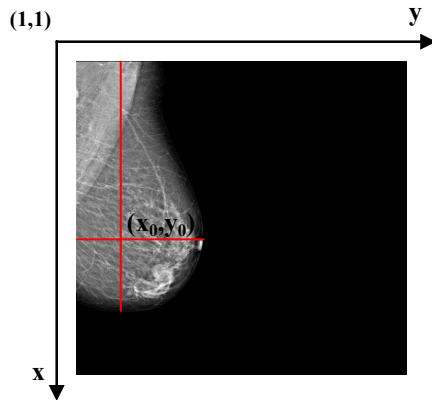


Fig. 2 – Example of breast centre detection

The breast centre has been taken as the starting point for a simple region growing algorithm. The reason for making a simpler algorithm is rather large size of each image (4084×3328) because of which standard region growing algorithm takes too much calculation time. This method works, as expected, very well on digital mammography images. It gives 100% success ratio on our set of 40 digital mammography images, from 20 different patients.

III. PECTORAL MUSCLE

Pectoral muscle detection is one more challenging task in the breast segmentation process. Reason for detecting pectoral muscle is to remove it or to find some key-points in mammography image so it can be registered afterwards. Registration can help in some auto detect procedures such as finding bilateral asymmetry. The algorithm for pectoral muscle segmentation proposed in this paper consists of few steps as shown in Fig. 3.

Technique for segmenting pectoral muscle presented in this paper uses wavelet decomposition, image blurring and edge detection using the Sobel filter. To detect pectoral muscle it is necessary to know the breast orientation. If the breast orientation is known, it is easy to select the region on which segmentation technique will be applied. Segmentation starts by automatically selecting the desired region. The region of interest containing pectoral muscle is determined by three points. For example, if the image shows MLO view of the right breast, the first point A is top left corner of the image with coordinates (1,1). The second point B is determined by the contour of skin-air interface and the third point C is chosen to be approximately at half of image height while satisfying the condition that x_c equals to the power of two (2^n). This condition is helpful when using wavelet decomposition, because it is important that image height is multiple of 2^n for proper use of wavelet decomposition. By those three points a rectangle is determined as shown in Fig. 4.

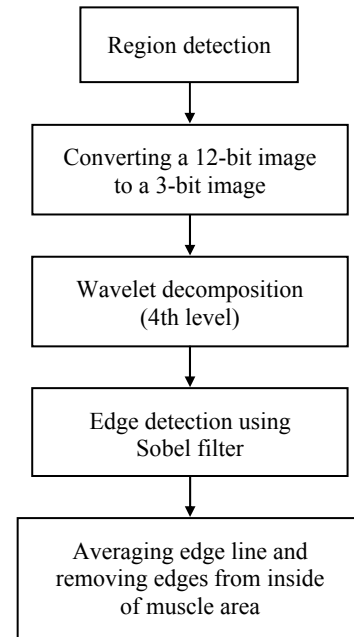


Fig. 3 – Flowchart of pectoral muscle detection algorithm

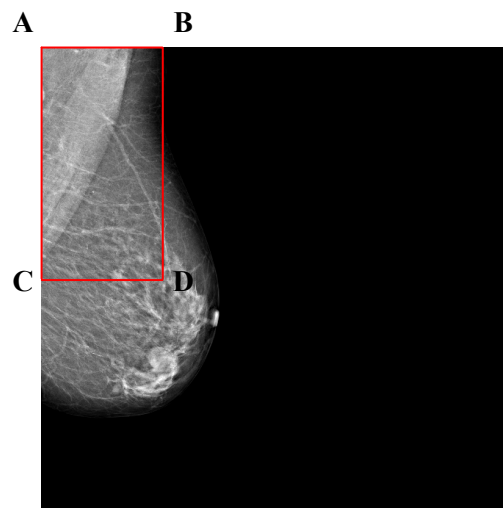


Fig. 4 – Rectangle with the pectoral muscle

After determining the region where pectoral muscle should be detected, the image of the region is supplemented with zeros to get the image with size $2^n \times 2^n$ as shown in Fig. 5.

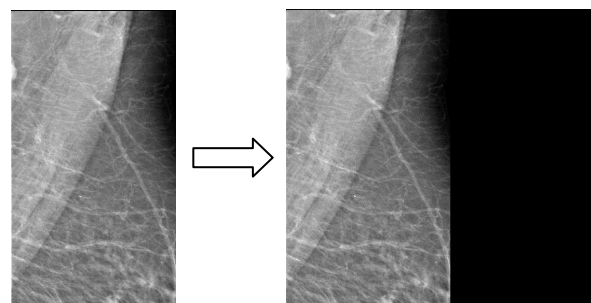


Fig. 5 – Pectoral muscle region image supplemented with zeros to get the image with size $2^n \times 2^n$

Before proceeding with wavelet decomposition, image intensity levels are grouped into 8 bins as shown in Fig. 6. This gives a 3-bit image from a 12-bit start image. Reduction in bit depth helps in better defining pectoral muscle region. That is possible because muscle tissue is mostly uniform density. Since original image is in TIFF image format with 12 allocated bits and information in these images is not contained in all 12 bits, it is necessary to make "windowing" of amplitudes that contain information. This has been done using the algorithm for displaying mammography images correctly as described in [19].

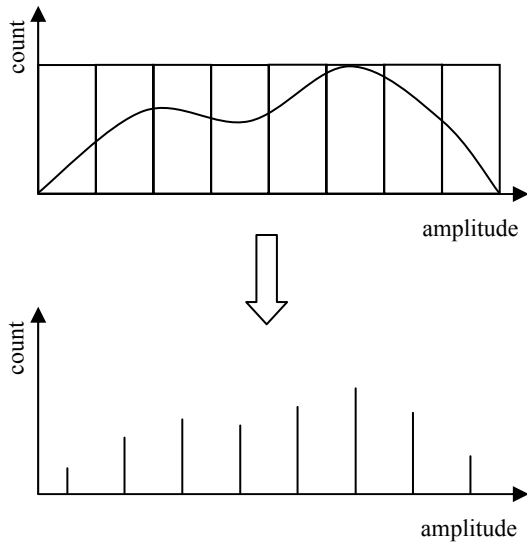


Fig. 6 – Grouping amplitude ranges into discrete amplitudes

Grouping intensity levels to a few bins is a way of contrast enhancement and results are visible when comparing images shown in Fig. 7.

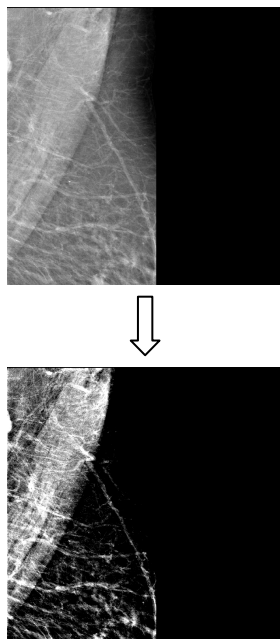


Fig. 7 – The same image before and after converting amplitude range to 8 discrete amplitudes

On a new 3-bit image a dyadic wavelet decomposition of fourth level is being done using algorithm described in [20]. Approximation image of the fourth level wavelet decomposition gives the best results for detecting larger structures, such as pectoral muscle. Fig. 8 shows example of the third level dyadic wavelet decomposition, where HP are high pass components (detail images) and LP are low pass components (approximation images).

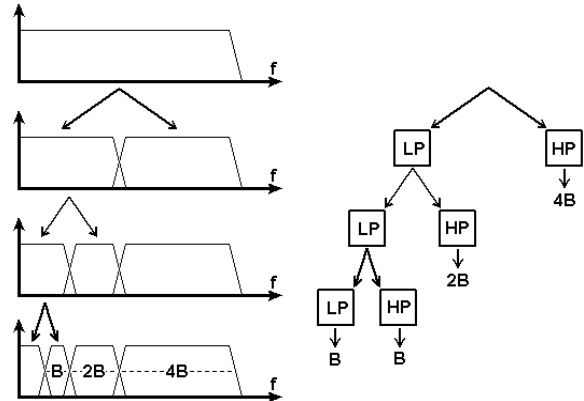


Fig. 8 – Example of the third level dyadic wavelet decomposition

The fourth level decomposition gives the best results because it preserves enough "rough" details while at the same time does a very good job in removing fine details like noise and granulation. Use of different wavelet filter banks gives different results. In this paper, a reverse biorthogonal spline wavelet filter has been used, Fig. 9.

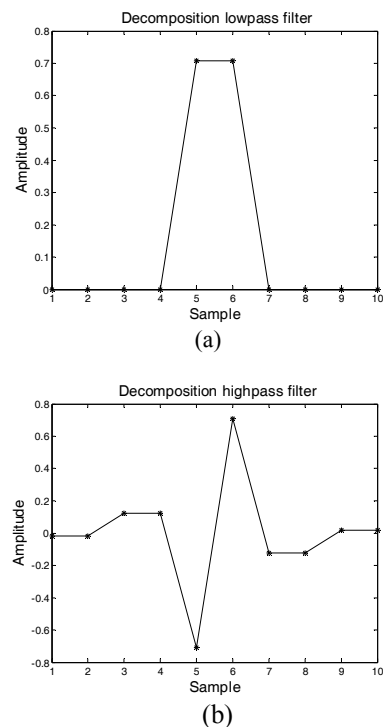


Fig. 9 – Reverse biorthogonal spline wavelet filter: (a) decomposition lowpass filter, (b) decomposition highpass filter

The approximation image is then interpolated using wavelet based interpolation technique [21] to get the image that is the same size and brightness as the original decomposed image. Fig. 10 shows the original and the decomposed image after interpolation.

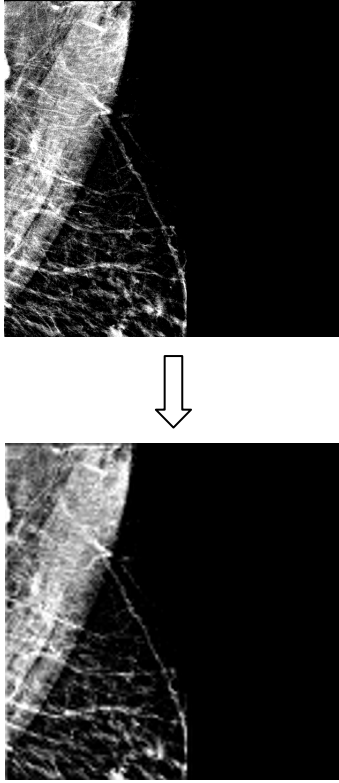


Fig. 10 – Original image and interpolated approximation image after the fourth level wavelet decomposition

Since the interpolated image is also granulated, a blurring filter is used to get smoother edges before thresholding and edge detection. For blurring an averaging square filter of size 40×40 pixels has been chosen, where each cell $(\alpha_{i,j})$ is defined by (1).

$$(\alpha_{i,j}) = \frac{1}{n \cdot n}, \quad (1)$$

where n is matrix height and width.

Thresholding of the blurred image gives better results because gray amplitudes are more evenly spread, giving a straighter line, more similar to the muscle boundary. After thresholding, gradient filtering (2) using the Sobel filter with matrix size 3×3 shown in Fig. 11 is used to detect muscle edges:

$$\nabla f = \text{grad}(f) \equiv \begin{bmatrix} g_x \\ g_y \end{bmatrix} = \begin{bmatrix} \frac{\partial f}{\partial x} \\ \frac{\partial f}{\partial y} \end{bmatrix}, \quad (2)$$

where f is image gradient defined by two orthogonal components, g_x and g_y .

$$g_x = \begin{bmatrix} -1 & -2 & -1 \\ 0 & 0 & 0 \\ 1 & 2 & 1 \end{bmatrix}$$

$$g_y = \begin{bmatrix} -1 & 0 & 1 \\ -2 & 0 & 2 \\ -1 & 0 & 1 \end{bmatrix}$$

Fig. 11 – Sobel gradient matrices for edge detection in vertical (g_x) and horizontal (g_y) direction

Another smoothing is required to get cleaner boundary after the edge detection. Edges that were detected by the Sobel filter inside the pectoral muscle region are removed by approximating muscle boundary with a straight line (3) that connects upper right corner and lower left corner of muscle region in the case of the right breast image:

$$y = y_1 + \frac{y_2 - y_1}{x_2 - x_1}(x - x_1), \quad (3)$$

where x_i and y_i are coordinates of points that create a straight line.

This approximation works well because the pectoral muscle border is either straight line or slightly concave curve. The muscle contour is then easily found and pixel values can be used for the muscle removal in the original image or to calculate parameters for the image registration.

IV. EXPERIMENTAL RESULTS

Algorithm proposed in this paper is tested on a set of 40 MLO digital mammography images, from 20 different patients (2 images from each patient). Each image has resolution of 4084×3328 pixels with 12 bits per pixel. The image format is uncompressed TIFF. All images are stored in compliance with Dicom standard. Mammography imaging device is MAMMOMAT Novation^{DR}, manufactured by Siemens, that has α -Selenium direct conversion detector and uses Wolfram/Rhodium anode/filter combination [22].

Skin-air interface or breast border contour detection gave excellent results with success ratio of 100%. Reason for this success lies in high quality of our experimental image set (digital mammography images commonly used in today's medical imaging). Every image has well defined background, what makes thresholding easier and simple region growing in four directions from defined breast centre as a seed point gives excellent results.

Fig. 12 shows example of breast border image superposed to original image. The border contour is defined as the first pixel with background intensity outside of the breast region.

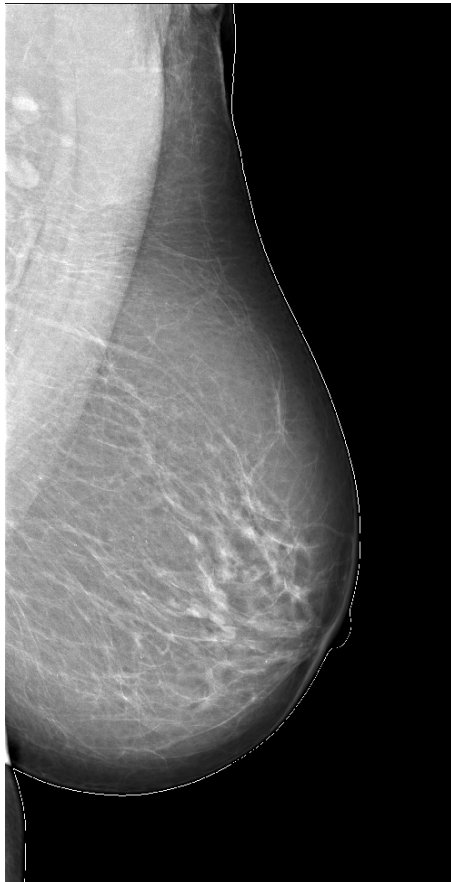

Fig. 12 – Breast border contour; breast segmentation from the background

Fig. 13 shows a detail of detected border around nipple region.

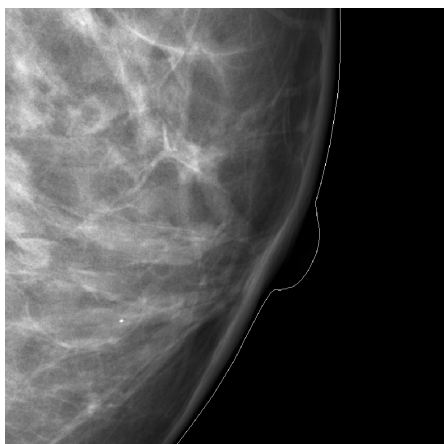


Fig. 13 – Detected breast border contour around nipple region

Pectoral muscle detection is a more complex problem than breast border contour detection. Technique presented in this paper uses wavelet decomposition to obtain the image with less fine details and smoother muscle line for edge detection. In Fig. 14 an example of the approximation image after the fourth level wavelet decomposition is shown.



Fig. 14 – Approximation image of fourth level wavelet decomposition

After wavelet decomposition the edges are found using the Sobel filter. The resulting image is then blurred using averaging filter to get smoother line and the edges inside muscle area are removed. Result of this process is shown in Fig. 15.




Fig. 15 – Image obtained after edge detection and line smoothing

Results of segmentation process are shown in Fig. 16 where pectoral muscle segmentation line is superposed to the segment of the image that contains detected pectoral muscle.

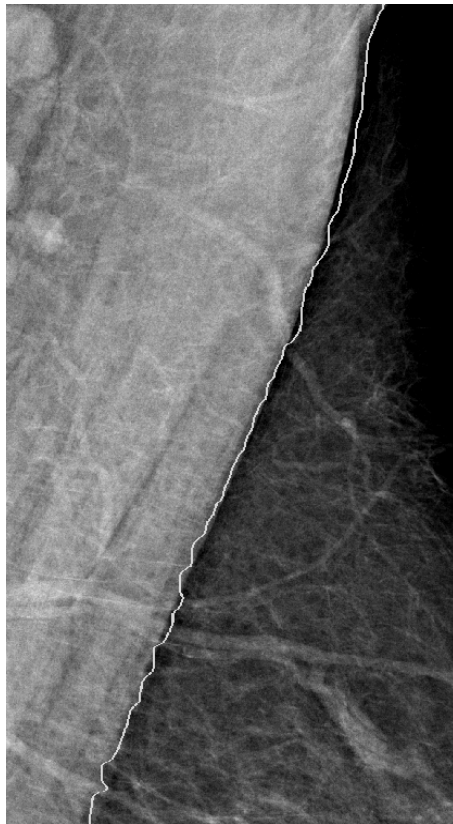


Fig. 16 – Pectoral muscle segmentation line superposed to original image

Results of pectoral muscle segmentation are divided in three groups and shown in Table 1. Total percentage for "Good", "Acceptable" and "Unacceptable" results are shown at the end of each column.

Table 1. Pectoral muscle segmentation results

Result	Good	Acceptable	Unacceptable
Total No. (40)	19	15	6
Percentage	47.5%	37.5%	15%
	85%		15%

V. CONCLUSION

In this paper a method for the detection of the breast border contour and the pectoral muscle segmentation is presented.

The proposed method for detecting the breast border contour works well on our test set containing 40 digital mammography images. This method gave 100% success in detecting the correct skin-air

interface. The main reason for that is very good quality of tested images because of the preprocessing stage done by the mammography device. Screen film mammography image breast border detection would not be near as successful as the same detection on digital mammography images because scanned SFM images are not preprocessed and film often contains artifacts that can cause problems in automatic detection. Advantage of this method is low algorithm complexity and therefore short processing time. Border contour can easily be used for the image registration process and segmented breast region for a histogram based image optimization. Our further research will focus on detection of skin tissue outside of the breast region in order to make even better segmentation.

Pectoral muscle detection proved to be a more challenging task because it is not very well differentiated from the surrounding breast tissue. Each mammography image has different intensity variation of the pectoral muscle and the surrounding tissue and therefore contrast based methods have problems in segmenting it correctly. The method proposed in this paper uses contrast enhancement by converting groups of intensities from original image to 8 discrete values, creating a 3-bit image. This helps in making edges easier to spot and to detect using gradient filtering. Wavelet decomposition is used to make an image that contains fewer details than the original one that results in fewer detected edges. This approach works well because pectoral muscle is rather large object for detection. Further development concerns smoothing of the pectoral muscle segmentation line as well as finding the method that gives better results in automatic thresholding before edge detection filtering.

ACKNOWLEDGMENT

The work described in this paper was conducted under the research project "Intelligent Image Features Extraction in Knowledge Discovery Systems" (036-0982560-1643), supported by the Ministry of Science, Education and Sports of the Republic of Croatia.

Authors would like to thank Prof. Boris Brljacic, Dr. Renata Huzjan Korunic and Mr. Milan Grzan from the Department of Diagnostic and Interventional Radiology, University Hospital "Dubrava", Zagreb, Croatia, for providing digital mammography images.

REFERENCES

- [1] Suckling J., Parker J., Dance D.R., Astley S., Hutt I., Boggis C.R.M., Ricketts I., Stamatakis E., Cernaes N., Kok S.L., Taylor P., Betal D., Savage J., "The Mammographic Image Analysis Society Digital Mammogram Database", Proceedings of the 2nd International Workshop on Digital Mammography, York, England, 10–12 July 1994, Elsevier Science, Amsterdam, The Netherlands, pp. 375-378.

- [2] Heath M., Bowyer K., Kopans D., Moore R., Kegelmeyer P. Jr., "The Digital Database for Screening Mammography", Proceedings of the 5th International Workshop on Digital Mammography, Toronto, Canada, 11-14 June 2000, Medical Physics Publishing, 2001, pp. 212-218.
- [3] Kallergi M., Woods K., Clarke L.P., Qian W., Clark R.A., "Image Segmentation in Digital Mammography: Comparison of Local Thresholding and Region Growing Algorithms", Computerized Medical Imaging and Graphics, **16** (5) (1992), pp. 323-331.
- [4] Chandrasekhar R., Attikiouzel Y., "Gross Segmentation of Mammograms using a Polynomial Model", Proceedings of the 18th Annual International Conference of the IEEE Engineering in Medicine and Biology Society, Amsterdam, The Netherlands, 31 October - 3 November 1996, pp. 1056-1058.
- [5] Bick U., Giger M., "Automated Segmentation of Digitized Mammograms", Academic Radiology, **2** (1995), pp. 1-9.
- [6] Méndez A., Tahoces P., "Automatic Detection of Breast Border and Nipple in Digital Mammograms", Computer Methods and Programs in Biomedicine, **49** (1996), pp. 253-262.
- [7] Zhou C., Chan H., "Computerized Image Analysis: Estimation of Breast Density on Mammograms", Medical Physics, **28** (2001), pp. 1056-1069.
- [8] Raba D., Oliver A., Martí J., Peracaula M., Espunya J., "Breast Segmentation with Pectoral Muscle Suppression on Digital Mammograms", Proceedings of the 2nd Iberian Conference (IbPRIA 2005), Estoril, Portugal, 7-9 June 2005, Pattern Recognition and Image Analysis, Springer-Verlag, Heidelberg, 2005, pp. 471-478.
- [9] Godsitt M., Chan H., "Classification of Compressed Breast Shapes for the Design of Equalization Filters in x-ray Mammography", Medical Physics, **25** (1998), pp. 937-947.
- [10] Ferrari R.J., Rangayyan R.M., Desautels J.E.L., Frère A.F., "Segmentation of Mammograms: Identification of the Skin - air Boundary, Pectoral Muscle, and Fibroglandular Disc", Proceedings of the 5th International Workshop on Digital Mammography, Toronto, Canada, 11-14 June 2000, Medical Physics Publishing, 2001, pp. 573-579.
- [11] Wirth M., Stapinski A., "Segmentation of the Breast Region in Mammograms using Snakes", Proceedings of the 1st Canadian Conference on Computer and Robot Vision (CRV 2004), London, Ontario, Canada, 17-19 May 2004, pp. 385-392.
- [12] Mencattini A., Salmeri M., Lojaco R., Frigerio M., Caselli F., "Mammographic Images Enhancement and Denoising for Breast Cancer Detection Using Dyadic Wavelet Processing", IEEE Transactions on Instrumentation and Measurement, **57** (7) (2008), pp. 1422-1430.
- [13] Homer M.J., "Mammographic Interpretation: A Practical Approach", McGraw-Hill, Boston, MA, 1997.
- [14] Karssemeijer N., "Automated Classification of Parenchymal Patterns in Mammograms", Physics in Medicine and Biology, **43** (2) (1998), pp. 365-378.
- [15] Ferrari R.J., Rangayyan R.M., Desautels J.E.L., Borges R.A., Frère A.F., "Automatic Identification of the Pectoral Muscle in Mammograms", IEEE Transactions on Medical Imaging, **23** (2) (2004), pp. 232-245.
- [16] Aylward S.R., Hemminger B.M., Pisano E.D., "Mixture Modeling for Digital Mammogram Display and Analysis", Digital Mammography, Computational Imaging and Vision, **13** (1998), pp. 305-312.
- [17] Mirzaalian H., Ahmadzadeh M.R., Sadri S., "Pectoral Muscle Segmentation on Digital Mammograms by Nonlinear Diffusion Filtering", Proceedings of the IEEE Pacific Rim Conference on Communications, Computers and Signal Processing, Victoria, B.C., Canada, 22-24 August 2007, pp. 581-584.
- [18] Kwok S.M., Chandrasekhar R., Attikiouzel Y., Rickard M.T., "Automatic Pectoral Muscle Segmentation on Mediobasal Oblique View Mammograms", IEEE Transactions on Medical Imaging, **23** (9) (2004), pp. 1129-1140.
- [19] Muštra M., Grgić M., Delac K., "Efficient Presentation of DICOM Mammography Images using Matlab", Proceedings of the 15th International Conference on Systems, Signals and Image Processing (IWSSIP), Bratislava, Slovakia, 25-28 June 2008, pp. 13-16.
- [20] Sprljan N., Grgić S., Grgić M., "Selection of Biorthogonal Filters for Wavelet Image Compression", Proceedings of the 10th International Workshop on Systems, Signals and Image Processing, IWSSIP'03, Prague, Czech Republic, 10-11 September 2003, pp. 48-52.
- [21] Dumic E., Grgić S., Grgić M., "The Use of Wavelets in Image Interpolation - Possibilities and Limitations", Radioengineering, **16** (4) (2007), pp. 101-109.
- [22] Siemens, Mammomat NovationDR, Available at: www.medical.siemens.com

Mario Muštra received the B.Sc. degree in electrical engineering from University of Zagreb, Faculty of Electrical Engineering and Computing, Zagreb, Croatia in 2007. He is currently working as a Research Assistant at the Department of Wireless Communications, University of Zagreb Faculty of Electrical Engineering and Computing. His area of interest includes (medical) image processing, CAD systems and pattern recognition.

Jelena Božek received the B.Sc. degree in electrical engineering from University of Zagreb, Faculty of Electrical Engineering and Computing, Zagreb, Croatia in 2008. She is currently a Research Assistant at the Department of Wireless Communications, Faculty of Electrical Engineering and Computing, University of Zagreb, Croatia. Her research interests include image processing and digital mammography.

Mislav Grgić received the B.Sc., M.Sc. and Ph.D. degrees in electrical engineering from University of Zagreb, Faculty of Electrical Engineering and Computing, Zagreb, Croatia, in 1997, 1998 and 2000, respectively. He is currently an Associate Professor at the Department of Wireless Communications, Faculty of Electrical Engineering and Computing, University of Zagreb, Croatia. His research interests include multimedia communications and image processing. He published more than 110 scientific papers in international journals and conference proceedings.